

The use of Algivon® in the treatment of a traumatic amputation to the right ring finger distal to the DIP joint

Angela Crespin - Clinical Support Nurse, Waikanae Health, New Zealand

Case study

Mr. M is a 54 year old self-employed contractor. He suffered a traumatic amputation to his right ring finger distal to the DIP joint caused by a pulley at work. The accident happened at 8am on 24th January 2013 and was dressed by his colleagues.

Mr. M was seen at Kenepuru Hospital at 5pm that day. The finger stump was not bleeding and had an almost straight (horizontal) amputation distal to the DIP joint; a tiny half moon of nail remains. Mr. M was able to flex both the PIP and DIP joints independently. The bone is visible.

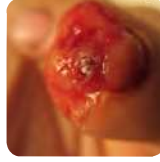Kenepuru Hospital recommended that the patient be referred to Hutt Plastics Department for a surgical amputation of the finger tip at the PIP joint. The Doctor at KPH recommended surgery, as conservative treatment would mean longer healing time and a higher risk of infection. Mr. M declined the surgical option and wished to visit his own GP for treatment.

Mr. M came to the GP surgery the following day. The right ring finger was a very meaty wound with a blood clot sitting in the centre. The surgery option was discussed again in depth, however Mr. M declined as he wished to continue with conservative treatment consisting of the use of Algivon® alginate dressing impregnated with 100% Manuka honey.

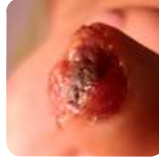The patient was reviewed for traumatic amputation of the right ring finger tip, occurring 4 days ago. The wound bed was healthy and clean with no visible signs of infection. Mr. M consented to photographs being taken to be used for educational purposes. A treatment plan was agreed between Mr. M, his GP and the wound nurse of the daily use of Algivon®.

Dressing Regime

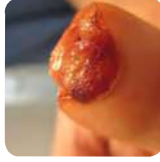A daily dressing regime commenced. Normal saline was used to clean the wound and Algivon® used as the primary dressing. Interpose Lite was used as a secondary dressing with a Gauze padding and Tubifast to secure the dressings.



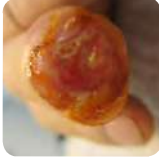Initial assessment



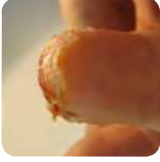31 January 2013



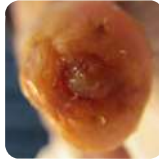7 February 2013



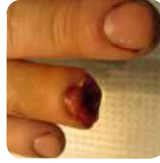15 February 2013



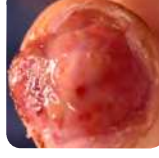22 February 2013



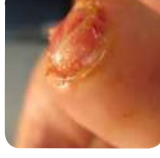1 March 2013



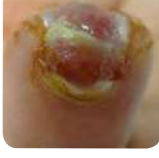30 January 2013



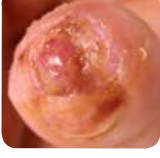4 February 2013



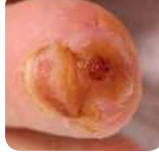11 February 2013



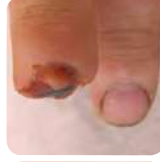18 February 2013



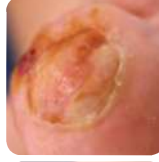25 February 2013



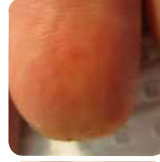4 March 2013



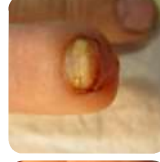
8 March 2013



22 March 2013



22 March 2013

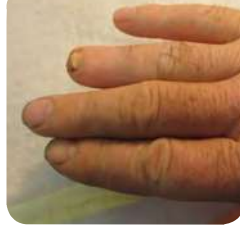

22 March 2013

Summary of Treatment

The wound took 8 weeks to heal with the conservative treatment. No further antibiotics were required after the initial course prescribed by KPH. Mr. M could continue to work with no loss of income. The wound was pain free most days and the treatment met Mr. M's expectations.

Mr. M has sensation and full movement in his finger and was very happy with the final result.



22 March 2013 final review, finger tip healed and nail growing.

